

Effect of adding platelet-rich plasma to fat grafts in myringoplasty

Tamer Fawzy, Mohamed Hussein, Said Eid, Sherif Guindi

ENT Department, Faculty of medicine, Fayoum University, Fayoum, Egypt

Correspondence to Tamer Fawzy MD, 197B 26TH July street 12411. Tel: 0233452076; fax: 0233452410; e-mail: drfawzyt@gmail.com

Received 3 July 2018

Accepted 24 September 2018

The Egyptian Journal of Otolaryngology
2018, 34:224–228

Background

Platelet-rich plasma (PRP) is an autologous product derived from whole blood through the process of gradient density centrifugation. Autologous PRP, with growth factors up to 8 times that of normal serum, has been shown to be safe and effective in promoting natural processes of wound healing. Our study aims to examine the effect of combining the fat graft with PRP in myringoplasty procedures indicated for TMP secondary to chronic suppurative otitis media (CSOM) and whether it can significantly promote Tympanic membrane (TM) healing.

Methods

This prospective study included forty patients, presenting with dry tympanic membrane secondary to tubo-tympanic CSOM. Half the patients underwent fat graft Myringoplasty with PRP application (group A), while others served as control and received the fat graft only, without PRP (group B).

Results

In group A, eighteen cases (90%) significantly showed an intact tympanic membrane, while Eleven cases (55%) were successful in group B. $P=0.044$.

Conclusion

Topical autologous PRP application during fat plug Myringoplasty is highly successful with no reported postoperative infections and minimal morbidity.

Keywords:

fat graft, myringoplasty, platelet rich plasma

Egypt J Otolaryngol 34:224–228

© 2018 The Egyptian Journal of Otolaryngology

1012-5574

Introduction

Tympanic membrane perforations (TMPs) are particularly common in our community. Although 88% of cases heal spontaneously, we perform more than 100 procedures annually in our university teaching hospital [1]. Various grafting materials have been used to reconstruct the TM, including skin, fascia, vein, fat, perichondrium, dura mater, and cartilage. Temporalis fascia is the most frequently used grafting material. Fat grafts are easier to harvest; however, they are known to be absorbable. Performing simple fat plug myringoplasty, defined here as the closure of TMPs without elevation of the annulus, is usually reserved for small, traumatic perforations [1–3]. Complementing the fat graft with platelet-rich plasma (PRP) to render the graft more stable can encourage the use of fat grafts in larger perforations. PRP is an autologous product. Platelets are key factors in tissue repair mechanisms. They provide essential growth factors, which stimulate fibroblasts and endothelial cells to create extracellular matrix deposition and neovascularization. Plasma contains many factors essential for cell survival, including nutrients, vitamins, hormones, electrolytes, growth factors, and proteins. They serve as a promoter for cell migration and new tissue generation [4,5].

PRP is derived from whole blood through the process of gradient density centrifugation. Autologous PRP, with growth factors up to eight times that of normal serum, has been shown to be safe and effective in promoting natural processes of wound healing. Our study aimed to examine the effect of combining the fat graft with PRP in myringoplasty procedures indicated for TMP secondary to chronic suppurative otitis media and whether it can significantly promote TM healing [1,6].

PRP was developed in the 1970s and was first used by Ferrari in Italy in 1987 in cardiothoracic surgery. PRP therapy began gaining popularity in the mid-1990s. It has since been applied to many different medical fields such as cosmetic surgery, dentistry, sports medicine, and pain management [4].

Patients and methods

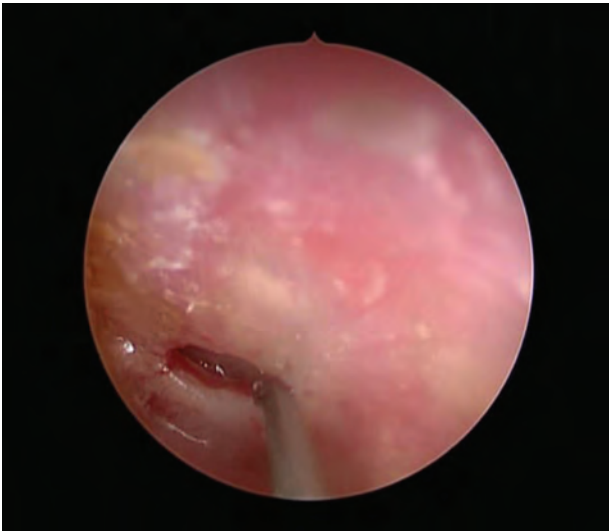
This prospective study included 40 patients selected from the ENT Outpatient Clinic of Fayoum University

This is an open access journal, and articles are distributed under the terms of the Creative Commons Attribution-NonCommercial-ShareAlike 4.0 License, which allows others to remix, tweak, and build upon the work non-commercially, as long as appropriate credit is given and the new creations are licensed under the identical terms.

Table 1 Demographic characteristics in both groups

Variables	Group A: fat and PRP (N=20) (mean±SD)	Group B: fat (N=20) (mean±SD)	P value
Age (years)	28.5±5.9	28.6±6.2	0.979 (NS)

PRP, platelet-rich plasma.

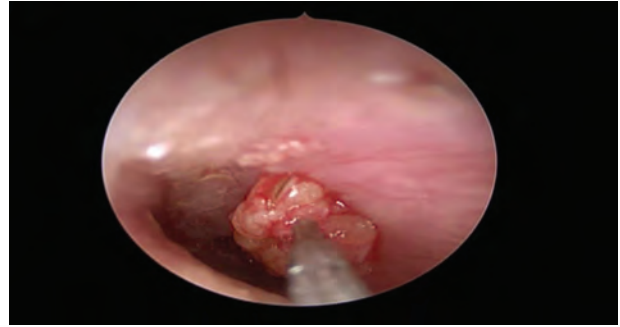
Fig. 1

Edges of the perforation are freshened.

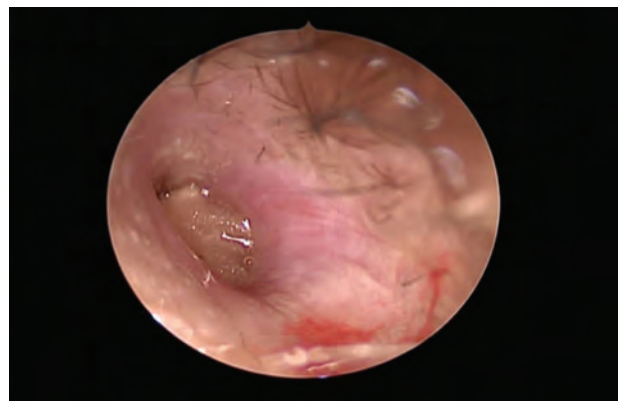Hospital presenting with a dry TM secondary to tubotympanic chronic suppurative otitis media. All patients participated voluntarily in our study and were consented for the procedures. The study was approved by the ethics committee in our university teaching hospital. Half the patients underwent myringoplasty with fat graft and PRP, while the other half served as controls and received the fat graft only. Their ages ranged from 25 to 35 years with a mean of 28.5 ± 5.9 years. Twenty (50%) patients were men and 20 (50%) were women (Table 1).

Records of age, gender, perforation site on the TM, laterality, and the perforation size were documented. All patients were examined microscopically in our outpatient clinic. Pure tone audiometry (PTA) and radiography Schuller view were performed for all patients. Written consents were obtained for all procedures.

Our inclusion criteria were as follows: adult patients with TMP in which all edges were visible, a dry ear for at least 1 month before surgery, and presence of the perforation for at least 6 weeks. Exclusion criteria were as follows: actively discharging ears, recurrent perforations due to failed previous tympanoplasty, the absence of anterior rim, cholesteatoma, and patients requiring ossicular reconstruction.

Fig. 2

The fat graft being placed in the perforation.

Fig. 3

Fat graft injected with PRP covered by gelfoam soaked with PRP.
PRP, platelet-rich plasma.

The patients were divided by a systemic random sampling method into two groups, with 20 patients in each group as follows:

Group A patients received a fat graft taken from the ear lobule, along with PRP.

Group B patients received a fat graft without PRP.

The sizes of TMP were also recorded according to the Saliba classification: sizes of the TMP according to the Saliba classification are defined as: 'small,' which is a perforation less than 25% the diameter of the TM. Medium is a perforation more than 25% and less than 50% the diameter of the TM. Large is a perforation more than 50% and less than 75% the diameter of the TM. Total: more than 75% the diameter of the TMP.

Operative details

Under general anesthesia, a 1×1-cm fat graft was harvested from the ear lobule. The graft was kept moist in 0.9% saline. Using a microscope, the edges of the perforation were freshened and a piece of gelfoam was placed in the middle ear (Fig. 1).

The fat plug graft was placed on the undersurface of the TM and bulged through the perforation (Fig. 2). Simultaneously, 10–20 ml of blood was collected from an antecubital vein and placed in an adenosine-citrate-dextrose-acid collection tube to prevent premature activation. The tube was carefully turned upside four to five times to homogenize blood with the anticoagulant. The blood was placed in the centrifuge at 3400 rpm for 5 min, during which the platelets were suspended in the plasma supernatant. The supernatant was removed and collected into a syringe. The supernatant was injected onto the surface of the fat graft and the rest added to a piece of gelfoam (Figure 3). Multiple pieces of gelfoam soaked with ofloxacin were applied on the fat plug and into the external canal. The patients were discharged on the same evening and advised against flying, nose blowing, and wetting the ear (Figs 1–3).

Clinical follow-up was carried out after 1, 3, and 6 months postoperatively to assess TM healing. Audiological follow-up by PTA was performed 3 months postoperatively. There were no evident postoperative complications.

Results

The collected data were organized, tabulated, and statistically analyzed using statistical package for the social sciences software (IBM SPSS, version 18; IBM Inc., Armonk, New York, USA). For quantitative data, the mean and SDs were calculated. The independent *t* test was used to compare the two groups, while the paired *t* test served to compare preintervention and postintervention readings within groups. Qualitative data were presented as numbers and percentages; χ^2 was used as a test of significance. To interpret results, significance was adopted at *P* value less than or equal to 0.05.

The patients were followed-up at 1, 3, and 6 months postoperatively. The criteria for success was based on complete closure of the TM. There was a statistically significant success rate achieved in patients in group A; 18 (90%) cases showed an intact TM, as opposed to 11 (55%) successful procedures in group B. One (5%) case, showed a residual TMP in group A and three (15%) cases in group B. In group A, in one (5%) case, the TMP remained unchanged, as opposed to six (30%) cases in group B, *P*=0.044 (Table 2).

In group A, the unsuccessful cases were one medium-sized perforation and one large-sized perforation, whereas success was achieved in eight and six patients respectively.

In group B the unsuccessful cases were six medium-sized perforations and three large-sized perforations, whereas success was achieved in five and three cases, respectively.

There were no small-sized perforation failures in both groups (Table 3).

The follow-up period showed no other complications such as lateralization or retraction.

The air–bone gap closure in both groups was statistically insignificant (Table 4).

Discussion

Although conventional tympanoplasty has a very high success rate of about 90%, there is continuous concern that there needs to be a simpler, less expensive, and less invasive alternative with comparable results [5].

Efforts to accelerate TMP healing have followed two main strategies: (a) stromal support to guide the regenerating

Table 2 Demographic characteristics in both groups

Variables	Group A: fat and PRP (N=20) [n (%)]	Group B: fat (N=20) [n (%)]	<i>P</i> value
Sex			
Male	11 (55.0)	9 (45.0)	0.527 (NS)
Female	9 (45.0)	11 (55.0)	

PRP, platelet-rich plasma.

Table 3 Healing in both study groups

Variables	Group A: fat and PRP (N=20) [n (%)]	Group B: fat (N=20) [n (%)]	<i>P</i> value
Healing			
Healed	18 (90.0)	11 (55.0)	0.044 (S)
Nonhealed	1 (5.0)	6 (30.0)	
Residual	1 (5.0)	3 (15.0)	

PRP, platelet-rich plasma; S, significant.

Table 4 Difference in pure tone audiometry before and after intervention in both study groups

	PTA		
Preoperative	23.00±4.70	23.00±4.70	1.000 (NS)
Postoperative	16.50±6.51	16.00±6.81	0.814 (NS)
% change	-28.3	-30.4	
P value	P<0.0001 (HS)	P<0.0001 (HS)	

HS, highly significant; PTA, pure tone audiometry.

tissue or (b) cellular regeneration and mobilization. The fat plug represents the former, whereas PRP represents the latter. Although fat is an easily accessible graft with minimal morbidity, adipose tissue has a high secretory activity, which produces numerous proinflammatory and proangiogenic proteins, resulting in high revascularization activity [3,7,8].

Paper patch myringoplasty is a well-known example of the former strategy, and it is an effective technique for small, clean perforations. A paper published in *The Laryngoscope* as recently as 2011 compares gelfoam plug myringoplasty with fat graft myringoplasty. The authors claim that closure rates are similar for both techniques, but gelfoam plug myringoplasty is a quicker and simpler technique. Such properties are beneficial to regenerate the epithelial layer of the healing TM. However, if applied alone on large TMPs, we noticed that it is resorbed before complete closure is achieved [9]. When using fat grafts to repair TMPs, it is important to harvest an amount of fat that is at least double the size of the perforation, because fat absorption is common [11].

Saliba and colleagues have been advocates of hyaluronic acid use in TMP cases. Hyaluronic acid, a natural component of the extracellular matrix of many body tissues, is known for its role in the regeneration and regulation of the fibrous layer during the healing process of the perforated TM. In addition, it supports and regulates the formation of keratin and hyperplastic epithelial tissue during healing. It also stimulates a centripetal migration of the epithelial layer over the temporary fat graft support [10,11]. Many studies have shown the advantages of applying local growth factors on the volume and survival of the fat graft. Adjunctives such as insulin, steroids, lidocaine, epinephrine, and selected β 1 blockers have been used to complement fat grafts to avoid its early absorption [3,12]. We chose to complement the fat plug graft with PRP because an autologous product seemed the most natural, rather holistic approach.

PRP is a biological product created by condensing platelets in vitro and activating the alpha granules

in order to stimulate secretion of growth factors. As it is prepared from autologous blood, PRP is cheaper than growth factors and carries no risk of transmitting infection. Use of PRP in the closure of tissue defects, particularly bone, has been reported [13,14].

In terms of graft healing, we achieved a 90% success rate in the patients who underwent fat plug myringoplasty plus PRP, which agrees with the work of Nakamura and colleagues. They compared fat graft healing with and without PRP by creating subcutaneous dorsal pockets in their empirical study on rats to show the effects of PRP on fat graft resorption. The authors found that capillary formation was significantly higher in the PRP group [15,16].

According to our results, small-sized perforations do not benefit from PRP as do large and medium-sized perforations. Many surgeons restrict the use of fat plug myringoplasty to small-sized traumatic perforation; however, many authors believe that the fat graft just needs an oval surface to stick, regardless of size [17]. We found the use of PRP to have no effect on hearing.

Alhabib and Saliba reported that complete closure was achieved in 18.1% of patients when using PRP. They abandoned the study due to the low success rate in patients having *autologous PRP myringoplasty*, albeit PTA was improved postoperatively in patients with closed TM [18]. According to Maria and colleagues, the use of PRP during myringoplasty will prevent graft displacement. Their study evaluated tympanic perforation repairs positively with lower morbidity for the patient and a perforation seal guarantee [4].

Although the use of autogenous fat grafts in head and neck surgery has been associated with some unpredictability, fat remains an excellent choice for obliterating frontal sinuses, for myringoplasty, and for limited soft tissue augmentation. In most applications, significant resorption of the transplanted fat can be expected, and it should be compensated for accordingly by initial overcorrection [19,20].

Conclusions

We found PRP to be a cheap and cost-effective platelet concentrate with an enriched growth factor. Topical autologous PRP application during fat plug myringoplasty is highly successful with no reported postoperative infections and minimal morbidity. It accelerates TM closure following fat plug myringoplasty and prevents graft displacement. It

also improves the overall success rate of fat plug myringoplasty. PRP not only enhances the healing of chronic TMPs but also avoids infection and obviates the need for inner ear packing.

Financial support and sponsorship

Nil.

Conflicts of interest

There are no conflicts of interest.

References

- 1 Marx RE. Platelet-rich plasma. A source of multiple autologous growth factors for bone grafts. In Lynch SE, Genco RJ, Marx RE, eds. *Tissue engineering: applications in maxillofacial surgery and periodontics* Chicago, IL: Quintessence Publishing Co. Inc. 1999 71–82.
- 2 Ringenber JC. Closure of tympanic membrane perforations by the use of fat. *Laryngoscope* 1978; 88:982–993.
- 3 Alzahrani M, Saliba I. Hyaluronic acid fat graft myringoplasty vs fat patch graft myringoplasty. *Eur Arch Otorhinolaryngol* 2015; 272(8):1873–1877.
- 4 Maria LNA, Ortiza N, Rodriguez L, Boemo R, Fuentes JF, Mateo A, Ortiz P. Pilot study on the efficiency of the biostimulation with autologous plasma rich in platelet growth factors in otorhinolaryngology: otologic surgery (tympanoplasty type I). *ISRN Surgery* 2011; 2011:451020.
- 5 Saliba I. Hyaluronic acid fat graft myringoplasty: how we do it. *Clin Otolaryngol* 2008; 33(6):610–614.
- 6 Saliba I, Froehlich P. (2011) Hyaluronic acid fat graft myringoplasty: an office-based technique adapted to children. *Arch Otolaryngol Head Neck Surg* 2011; 137(12):1203–1209.
- 7 Saliba I, Alzahrani M, Zhu T, Sylvain C. Growth factor expression in hyaluronic acid fat graft myringoplasty. *Laryngoscope* 2014; 124: E224–E230.
- 8 Erkilet E, Koyuncu M, Atmaca S, Yarim M. Platelet-rich plasma improves healing of tympanic membrane perforations: experimental study. *J Laryngol Otol* 2009; 123(5):482–487.
- 9 Niklasson A, Tano K. The Gelfoam® plug: an alternative treatment for small eardrum perforations. *Laryngoscope* 2011; 121:782–784.
- 10 Konstantinidis I, Malliari H, Tsakiropoulou E, Constantinidis J. Fat myringoplasty as an office based procedure. *Otorhinolaryngol Head Neck Surg* 2010; 42:25–28.
- 11 Nicholas B, Reilly R. Is cartilage preferable to fascia myringoplasty in children?. *Laryngoscope* 2010; 120(11):2136–2137.
- 12 Pacific L, Casella F. Maggiore Platelet rich Plasma: potentialities and techniques of extraxction. *Minerva Stomatol* 2002; 51:341–350.
- 13 Alhabib SF, Saliba I. Hyaluronic acid fat graft myringoplasty versus autologous platelet rich plasma. *J Clin Med Res* 2017; 9(1):30–34.
- 14 Kulkarni S, Kulkarni V, Burse K, Sancheti V, Roy G. Cartilage support for fascia graft in type I tympanoplasty. *Indian J Otolaryngol Head Neck Surg* 2014; 66(3):291–296.
- 15 KOÇ S. Fat graft myringoplasty with the newly developed surgical technique for chronic tympanic membrane perforation. *Eur Arch Otorhinolaryngol* 2013; 270:1–5.
- 16 Nakamura S, Ishiara M, Takikawa M, Murakami K, Kishimoto S. Platelet-rich plasma (PRP) promotes survival of fat-grafts in rats. *Ann Plast Surg* 2010; 65:101–106.
- 17 Gun T, Fatih O, Atan D, Ikinçiogullari A, Dere H. Comparison of hyaluronic acid fat graft myringoplasty, fat graft myringoplasty and temporal fascia techniques for the closure of different sizes and sites of tympanic membrane perforations. *J Int Adv Otol* 2016; 12(2):137–141.
- 18 Alhabib SF, Saliba I. Hyaluronic acid fat graft myringoplasty versus autologous platelet rich plasma. *J Clin Med Res* 2017; 9(1): 30–33.
- 19 Serra-Mestre JM, Serra-Renom JM, Martinez L, Almadori A, D'Andrea F. Platelet-rich plasma mixed-fat grafting: a reasonable pro survival strategy for fat grafts? *Aesthetic Plast Surg* 2014; 38:1041–1049.
- 20 Sergi B, Galli J, Corso E, Parrilla C, Paludetti G. Overlay versus underlay myringoplasty: report of outcomes considering closure of perforation and hearing function ;*Acta Otorhinolaryngol Ital.* 2011; 31(6): 366–371.