

# *EJO*

## *The Egyptian Journal of Otolaryngology*



**The Official Publication  
of the Egyptian Society of  
Otolaryngology**



**Providing a New Vision of our  
Ongoing Mission**

**Covering  
Otorhinolaryngology,  
Head and Neck Surgery,  
Audiology, Phoniatics,  
Basic Sciences**

**Volume 32    No. 1    January 2016**


**Contact Info: [Editorejo@gmail.com](mailto:Editorejo@gmail.com)**

**ISSN Print: 1012-5574**

**ISSN Online: 2090-8539**

**Medknow**

 **Wolters Kluwer**



# Endoscopic-assisted septoplasty versus traditional septoplasty: assessment by the NOSE scale

Guindi Sherif S., Mostafa Hany S., Fawzy Tamer O.

Department of Otolaryngology, Fayoum School of Medicine, Fayoum University, Fayoum, Egypt

Correspondence to Sherif Safwat Guindi, MD, 85 Ramses Street, Cairo, Egypt  
Tel: +20 225 762 711;  
e-mail: sguindi@yahoo.com

**Received** 05 June 2015

**Accepted** 31 July 2015

**The Egyptian Journal of Otolaryngology**  
2016, 32:26–31

## Context

Nasal obstruction is a very common complaint, which may be caused by various causes, one of the most important being septal deviation. Many techniques have been described to correct these septal deviations since the middle of 19th century. There have been several modifications since its inception. The application of endoscopic techniques to correct septal deformities was initially described by both Lanza and colleagues and by Stammberger in 1991.

## Aims

Comparing the efficacy of endoscopic septoplasty with traditional septoplasty in the treatment of cases with septal deviations.

## Patients and methods

Thirty cases complaining mainly of nasal obstruction due to significant septal deviations were selected. They were randomly divided into two groups: group A patients underwent endoscopic septoplasty and group B underwent traditional septoplasty. The Nasal Obstruction Symptom Evaluation (NOSE) scale was an important step in assessment.

## Results

The two procedures are suitable to correct septal deformities, with a slight upper hand for the endoscope in particular cases. We highlight in this study the advantages and disadvantages of the use of the nasal endoscope to correct nasal septal deviation.

## Conclusion

Although mainly used in sinus surgery, the endoscope has also found its way in nasal septal surgery as it facilitates accurate identification of the pathology due to better illumination, improved accessibility to remote areas and magnification. It allows precise resection of the pathological areas without the need of an extended dissection. Endoscopic septoplasty is associated with a significant reduction in the patient's morbidity in the postoperative period due to limited extent of flap dissection and limited manipulation and resection of the septal framework. However, the endoscope has its own limitations which include loss of binocular vision and the need for frequent cleaning. The NOSE scale also correlates well with the postoperative results of the study.

## Keywords:

endoscopic septoplasty, NOSE scale, septal deviation, traditional septoplasty

Egypt J Otolaryngol 32:26–31

© 2016 The Egyptian Oto - Rhino - Laryngological Society  
1012-5574

## Introduction

The repair of nasal septal deviation (septoplasty) is a time-honoured treatment for nasal airway obstruction. It is among the three most commonly performed procedures in otolaryngology [1]. Many techniques have been described previously to accomplish this goal [2]. Surgery of the septum, which started in its earlier days as a more radical surgery, later evolved into a more mucosal and cartilage framework preservation surgery [3]. Relatively poor illumination, accessibility and magnification demanded the use of a large exposure and the elevation of flaps on both sides of the septum. The introduction of the nasal endoscope has allowed for unnecessary over exposure and manipulation of the septal framework and better preservation of the nasal mucosa.

Nasal and sinus endoscopy have been available to rhinologist since the 19th century. It has become an

indispensable tool in the field of rhinology [4]. The nasal endoscope also allows precise preoperative identification of the septal pathology and its associated lateral nasal wall abnormalities and helps in better planning of endoscope-aided septal surgery [5].

In 1993, Lanza *et al.* [6] described a detailed endoscopic approach to the treatment of isolated septal spurs.

The Nasal Obstruction Symptom Evaluation (NOSE) scale is a disease-specific health status instrument used to assess patients with nasal obstruction. It is a

This is an open access article distributed under the terms of the Creative Commons Attribution-NonCommercial-ShareAlike 3.0 License, which allows others to remix, tweak, and build upon the work non-commercially, as long as the author is credited and the new creations are licensed under the identical terms.

recognized valid, reliable, and responsive instrument. It is also brief and easy to complete [7].

## Patients and methods

The study was conducted within the premises of the ENT Department of the Fayoum University Teaching Hospital on 30 patients presenting with nasal obstruction secondary to deviated nasal septum.

An informed consent was obtained from the participants and the study was conducted after approval from the faculty's ethic committee.

The patients presented with nasal obstruction as their main symptom accompanied in some cases by other minor, secondary complaints such as headache, postnasal discharge and/or hyposmia.

All patients underwent a full ENT examination with a preoperative diagnostic nasal endoscopy. We used the rod nasal endoscopes 0 and 30° to examine the nose and nasopharynx after the use of a local nasal decongestant and a local nasal spray anaesthetic. With the nasal endoscopy we noted the type, severity and site of the septal deviation, and whether in the cartilaginous or bony area.

Nasal endoscopy was also used to detect any area of contact between the nasal septum and adjacent turbinate or any nasal synechiae. Also, it was used to identify any hidden intranasal pathology.

A preoperative computed tomographic (CT) scan of the nose and paranasal sinuses (coronal and axial cuts) was carried out to exclude any paranasal sinuses pathologies.

Other associated symptoms and relevant history were also noted, such as headache, postnasal discharge, epistaxis, sneezing, the use of nasal decongestant drops or other medical treatment. Patients were asked about any history of previous nasal surgery. All these were tabulated for further reference and comparisons.

The 30 patients were randomly distributed by systematic random sampling method into two equal groups. The first group (group A) patients underwent endoscopic septoplasty, while the second group (group B) patients were scheduled for a traditional septoplasty as described by Cottle [8].

To quantify the patients' complaint and the severity of their condition, all patients answered the NOSE scale questionnaire. All surgeries were performed under general anaesthesia.

## Endoscopic septoplasty

### *Infiltration*

Infiltration of the nasal septum with 1 : 200 000 adrenaline in saline solution. In cases of isolated septal spur, we injected the mucosa under endoscopic vision just caudal to the spur.

### *Hemitransfixation*

A standard Killian incision.

### *Flap elevation*

A mucoperichondrial flap elevation was performed with a Cottle elevator.

Further elevation was done using the 0° Karl Storz nasal endoscopy held in the left hand, keeping the tip of the endoscope between mucoperichondrial flap and the septal cartilage. The right hand was used for instrumentation. The septal cartilage was then incised posterior to the mucosal incision. The contralateral mucoperichondrial flap elevation was then performed under endoscopic vision. Flap elevation was continued bilaterally and an inferior tunnel was created exposing any deviation in the maxillary crest or vomer.

We removed only the obstructing cartilage, leaving at least caudal and dorsal struts to maintain support of the nasal dorsum and columella. The cartilage was removed with a Luc's forceps or a Ballenger swivel knife. Any deviated bone only in the vertical plate of ethmoid was then removed under endoscopic vision with a Tilley Henkel forceps. If the maxillary crest was also deviated, we removed it using the gouge and hammer under endoscopic vision with the help of the assistant.

At the end of surgery, the flaps were inspected endoscopically and were sutured with 3-0 vicryl sutures. Both nasal cavities were packed with Merocel packs (Medtronic, Minnesota, USA).

## Traditional septoplasty

We used the same technique used in endoscopic approach as regards the infiltration, incision, flap elevation and removal of the obstructing cartilage or bone but without the aid of the endoscopes.

Patients were hospitalized for 2 days, during which they were observed for any nasal bleeding and were kept on oral antibiotic (augmentin 1 g) twice daily and oral anti-inflammatory drugs (Cataflam 50 mg) three times daily for 1 week.

The nasal packs were removed on the second postoperative day and the patients discharged. They were prescribed alkaline nasal spray for 1 month postoperatively. All

patients were evaluated twice weekly during the first week then once weekly for the next 3 weeks then every 2 weeks for 2 months. They were assessed for any residual deviation of the nasal septum especially residual spurs and to exclude septal perforation, adhesions and haematoma.

The nasal cavities were also suction-cleaned and crusts removed.

After 3 months we repeated the evaluation with the 'NOSE scale' to assess the improvement subjectively.

We also stressed about the improvement of other concomitant symptoms such as headache, snoring, postnasal discharge, epistaxis, hyposmia and sneezing.

The patients were also assessed for other complications such as pain, discomfort or epistaxis and investigated for any new symptoms that were not present preoperatively.

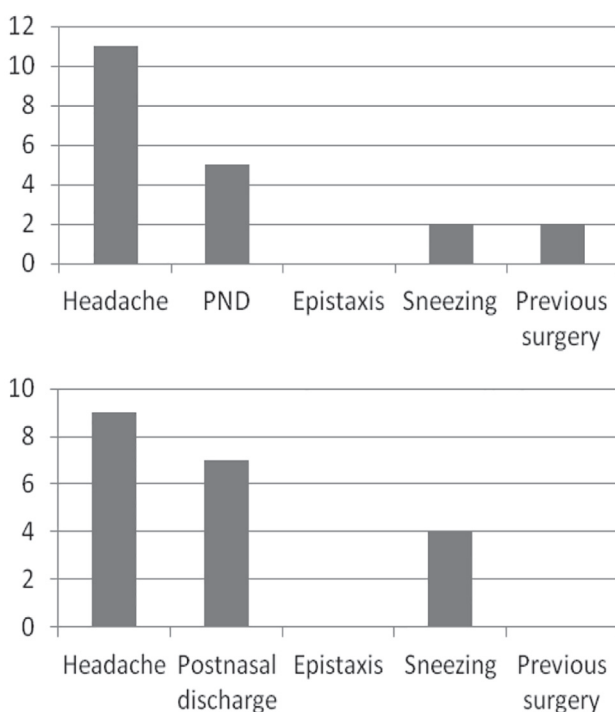
Lastly, a postoperative CT was performed, after the second questionnaire.

Preoperative and postoperative answers, results and imaging were tabulated and compared.

## Results

The preoperative results of the NOSE scale for both groups were as follows (the lower the NOSE scale

Figure 1



Preoperative evaluation in the two groups.

score, the lesser the subjective severity of the problem) (Fig. 1 and Table 1).

There was no significant difference in both the groups in the NOSE scale preoperatively ( $P = 0.9$ ) and in the associated symptoms; Headache ( $P = 0.7$ ), postnasal drip ( $P = 0.7$ ), and sneezing ( $P = 0.6$ ).

The duration of the surgery ranged in group A from 15 min in cases with isolated septal spur up to 50 min in cases with more than one septal deformity. However, in group B, it ranged from 25 up to 45 min.

As regards the early postoperative period, in group A patients, two patients had epistaxis upon removal of the pack 48 h postoperatively that was controlled by nasal ephedrine pack compressed for a few minutes. Mild pain and discomfort were experienced in six patients. No smell of bad odour, neither septal haematoma nor septal perforation was observed.

Within group B patients, four patients had epistaxis upon removal of the pack which was controlled as in group A. Mild pain and discomfort were experienced in eight patients. One patient had a smell of bad odour due to infection and crusting. Neither septal haematoma nor septal perforation was observed.

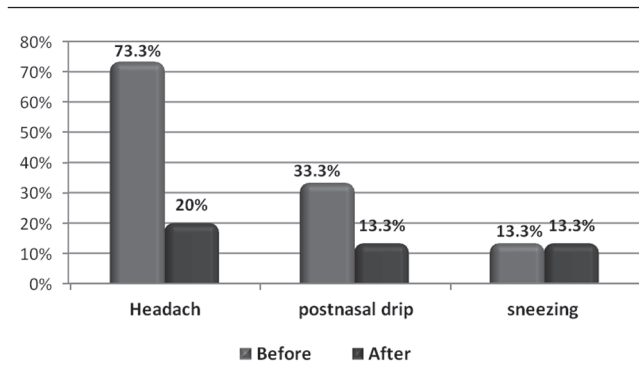
Analysis of the preoperative and postoperative NOSE scale questionnaire indicates that all patients reported an improvement in their sense of nasal obstruction. However, the degree of subjective improvement was more significant in the endoscopic septoplasty group when compared with the traditional septoplasty group ( $P = 0.009$ ) (Tables 2–7, Figs. 2 and 3).

Table 1 Preoperative NOSE score in groups A and B

Group A		Group B	
Case	NOSE score	Case	NOSE score
Case 1	14	Case 1	9
Case 2	11	Case 2	14
Case 3	9	Case 3	9
Case 4	9	Case 4	11
Case 5	10	Case 5	10
Case 6	8	Case 6	9
Case 7	15	Case 7	10
Case 8	11	Case 8	14
Case 9	10	Case 9	10
Case 10	10	Case 10	9
Case 11	9	Case 11	10
Case 12	10	Case 12	11
Case 13	14	Case 13	10
Case 14	11	Case 14	13
Case 15	10	Case 15	9

NOSE, nasal obstruction symptom evaluation scale.

Figure 2



Symptomatology (in %) preoperative and postoperative in group A.

Table 2 Postoperative NOSE score in groups A and B

Group A		Group B	
Case	NOSE score	Case	NOSE score
Case 1	4	Case 1	6
Case 2	3	Case 2	6
Case 3	2	Case 3	5
Case 4	6	Case 4	10
Case 5	9	Case 5	6
Case 6	5	Case 6	6
Case 7	4	Case 7	6
Case 8	9	Case 8	7
Case 9	3	Case 9	8
Case 10	4	Case 10	6
Case 11	5	Case 11	5
Case 12	7	Case 12	8
Case 13	3	Case 13	8
Case 14	4	Case 14	5
Case 15	3	Case 15	5

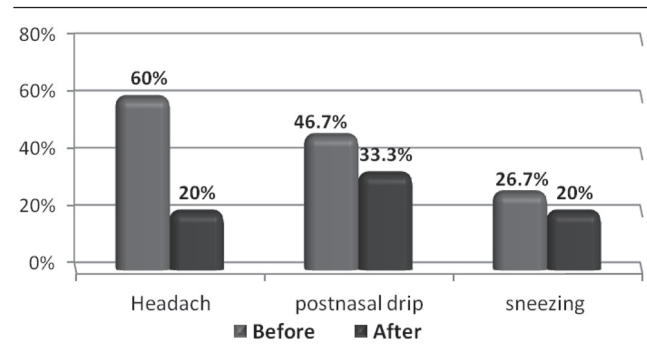
NOSE, nasal obstruction symptom evaluation scale.

Table 3 Postoperative symptomatic improvement in groups A and B

Symptom	Group A	Group B
	Patients improved	Patients improved
Headache	9	6
Postnasal discharge	3	5
Sneezing	0	1

As regards the objective follow-up, in group A two cases of minor deviation were found (case 5 and 8). Persistent spur was present in one patient (case 12). Only one patient had nasal crusting (case 8). Persistent contact between septum and turbinates was detected in one patient (case 5). No nasal synechiae, septal haematoma nor perforation was present. In group B, residual posterior deviations were present in four patients (case 4, 6, 9 and 13) and persistent spurs were noted in two patients (case 4 and 12). Nasal crusting was present in two patients (case 6 and 10). Persistent contact with the turbinates was observed in two patients (case 4 and 13). Neither septal haematoma nor perforation was present. Nasal synechiae were detected in one patient only (case 13).

Figure 3



Symptomatology (in %) preoperative and postoperative in group B.

Table 4 Comparison of associated symptoms in both groups postoperatively

Variables	Group A (n = 15) [n (%)]	Group B (n = 15) [n (%)]	P-value	Significance
Associated symptoms				
Headache	3 (20)	3 (20)	0.9	NS
Postnasal drip	2 (13.3)	5 (33.3)	0.4	NS
Sneezing	2 (13.3)	3 (20)	0.9	NS

Table 5 NOSE score preoperative and postoperative in group A

Group A (n = 15)	Nasal obstruction scale		P-value	Significance
	Mean	SD		
Before operation	10.7	4	0.001	HS
After operation	4.7	4.3		

HS, highly significant.

Table 6 NOSE score preoperative and postoperative in group B

Group B (n = 15)	Nasal obstruction scale		P-value	Significance
	Mean	SD		
Before operation	10.5	3.5	0.001	HS
After operation	6.4	2.8		

HS, highly significant.

Table 7 Postoperative comparison of NOSE scores in the two groups

Study group	Nasal obstruction scale after operation		P-value	Significance
	Mean	SD		
Group A (n = 15)	4.7	4.3	0.009	HS
Group B (n = 15)	6.4	2.8		

HS, highly significant; NOSE, nasal obstruction symptom evaluation scale.

## Discussion

The application of endoscopic technique to the correction of septal deformities was initially described in 1991 by Stammberger [9]. This has led to more research in the indication, technique and effectiveness

of the use of an endoscope in correction of septal deformities by many authors [5,10,11].

Our patients were all evaluated subjectively and objectively before and after the surgery, subjectively by the patient complaint and the NOSE scale questionnaire and objectively using the nasal endoscopy and CT scan imaging.

Nayak *et al.* [5] and Hwang *et al.* [12] used the nasal endoscopy alone as a postoperative objective assessment of nasal obstruction to compare between endoscopic septoplasty and traditional septoplasty. This single method of assessment was acknowledged by Sautter and Smith [13] as an excellent tool for outpatient surveillance following septoplasty during the initial postoperative healing period and beyond.

The NOSE scale correlated well with the clinical examination. This conclusion was also reported by Kahveci *et al.* [14] who gave an account on 27 patients and found that the NOSE scale correlates well with examination findings and CT and that it is a very useful tool to evaluate the effectiveness of septoplasty.

In our study, the preoperative data between both groups A and B were very comparable as regards age, sex, duration of nasal obstruction, associated symptoms and types of septal deformities indicating that any expected difference between the postoperative results of both groups was not dependant on these factors.

The duration of the surgical manoeuvres in endoscopic septoplasty was 15 min in cases with an isolated septal spur and up to 50 min in cases with more than one septal deformity. However, in traditional septoplasty, it ranged from 25 up to 45 min, which means that in cases with an isolated septal spur the duration of surgery is less when using the endoscope in comparison with the traditional method as under endoscopic vision; the incision is just caudal to the spur itself, which reduces the extent of the subperichondrial dissection.

Vanclooster and Jorissen [15] reported on a study conducted on 40 cases that endoscopic septoplasty in cases of posterior septal spur took on average less than 5 min. This also conforms to a study by Giles *et al.* [10] who reported that endoscopic septoplasty could be done in a relatively shorter period of time than traditional surgery in cases of isolated spur or limited deviation in the nasal septum.

Postoperative complications in our series were minimal, whether early or late complications.

Giles *et al.* [10] reported that out of the 38 procedures performed, five patients had small synechiae to the lateral nasal wall, and these were dealt with in the outpatient clinic and healed without difficulty. Also, there were no septal perforations in his study.

Gupta [16] reports one case of postoperative bleeding out of 48 cases.

Trimarchi *et al.* [17] using the endoscopic back-and-forth technique reported that out of 218 patients, early postoperative complications included transient dental pain or hypaesthesia in 15 patients, more intense on postoperative day 1 and recovered spontaneously after few days. Eleven patients developed septal haematoma that was subsequently evacuated. Postoperative synechiae involving the septum were found in five patients and were released under local anaesthesia in an outpatient setting. Four patients experienced postoperative epistaxis. Four patients developed septal perforations, three of which were small and asymptomatic and required no additional treatment and one perforation was anterior and corrective surgery was necessary.

We tend to notice a certain discrepancy between the various authors and studies concerning the incidence of early postoperative complications.

We also found that there is a good correlation between the results of the subjective and the objective assessments.

So, we believe endoscopic septoplasty to be superior to traditional septoplasty because of the following reasons:

- (1) It facilitates accurate identification of the pathology.
- (2) It allows better visualization and accessibility to the posterior deviations and spurs.
- (3) Endoscopic septoplasty is very useful in cases of isolated spurs as it limits dissecting area.
- (4) It is very useful as an effective teaching tool.
- (5) It allows better understanding of the lateral wall pathology associated with the septal deformity.
- (6) Instruments used in endoscopic septoplasty are similar to those used for functional endoscopic sinus surgery (FESS).
- (7) It allows correct identification of the cleavage planes of flap elevation especially in revision and posttraumatic cases. This minimizes chances of tears and prevents perforations.
- (8) Also, elevation of the flap in the correct plane minimizes intraoperative bleeding.
- (9) It helps in documentation of cases.

We report also some limitations to the use of nasal endoscopy:

- (1) No binocular vision.
- (2) The proximity of nasal endoscope to the surgical field results in frequent tip soiling and the need for intermittent cleaning of the endoscope tip.
- (3) No bimanual surgery.

#### Financial support and sponsorship

Nil.

#### Conflicts of interest

There are no conflicts of interest.

---

#### References

- 1 Siegel NS, Gliklich RE, Taghizadeh F, Chang Y. Outcomes of septoplasty. *Otolaryngol Head Neck Surg* 2000; 122:228–232.
- 2 Cantrell H. Limited septoplasty for endoscopic sinus surgery. *Otolaryngol Head Neck Surg* 1997; 116:274–277.
- 3 Maran AGD. Septoplasty. *J Laryngol Otol* 1974; 88:393–402.
- 4 Marks SC. *Nasal and sinus surgery*. Philadelphia: W. B. Saunders Co.; 2000. 59–63.
- 5 Nayak DR, Balakrishnan R, Murthy KD. An endoscopic approach to the deviated nasal septum – a preliminary study. *J Laryngol Otol* 1998; 112:934–939.
- 6 Lanza DC, Kennedy DW, Zinreich SJ. Nasal endoscopy & its surgical applications. In: Lee KJ, editor *Essential otolaryngology: head & neck surgery*. 7th ed. Elsevier Science Publishing Company, Inc. New York: 1999. 407–425.
- 7 Stewart MG, Witsell DL, Smith TL, Weaver EM, Yueh B, Hannley MT. Development and validation of the Nasal Obstruction Symptom Evaluation (NOSE) scale. *Otolaryngol Head Neck Surg* 2004; 130:157–163.
- 8 Brain D. The nasal septum. In: Kern AG, editor. *Scott-Brown's Otolaryngology*. 6th ed. Oxford: Butterworth-Heinemann; 1997; 4:11/1–11/27.
- 9 Stammberger H. *Functional endoscopic sinus surgery: the Messerklinger technique*. Philadelphia: BC Decker; 1991. 430–434.
- 10 Giles WC, Gross CW, Abram AC, Greene WM, Avner TG. Endoscopic septoplasty. *Laryngoscope* 1994; 104:1507–1509.
- 11 Park DH, Kim TM, Han DG, Ahn KY. Endoscopic-assisted correction of the deviated nose. *Aesthetic Plast Surg* 1998; 22:190–195.
- 12 Hwang PH, McLaughlin RB, Lanza DC, Kennedy DW. Endoscopic septoplasty: indication, technique, and results. *Otolaryngol Head Neck Surg* 1999; 120:678–682.
- 13 Sautter NB, Smith TL. Endoscopic septoplasty. *Otolaryngol Clin North Am* 2009; 42:253–260.
- 14 Kahveci OK, Miman MC, Yucel A, Yucedag F, Okur E, Altuntas A. The efficiency of Nose Obstruction Symptom Evaluation (NOSE) scale on patients with nasal septal deviation. *Auris Nasus Larynx* 2012; 39:275–279.
- 15 Vanclooster C, Jorissen M. Endoscopic septal spur resection in combination with endoscopic sinus surgery. *Acta Otorhinolaryngol Belg* 1998; 52:335–335339.
- 16 Gupta N. Endoscopic septoplasty. *Indian J Otolaryngol Head Neck Surg* 2005; 57:240–240243.
- 17 Trimarchi M, Bellini C, Toma S, Bussi M. Back-and-forth endoscopic septoplasty: analysis of the technique and outcomes. *Int Forum Allergy Rhinol* 2012; 2:40–4044.