

EJO *The Egyptian Journal of Otolaryngology*



**The Official Publication
of the Egyptian Society of
Otolaryngology**



**Providing a New Vision of our
Ongoing Mission**

**Covering
Otorhinolaryngology,
Head and Neck Surgery,
Audiology, Phoniatics,
Basic Sciences**


Volume 34 No. 1 January-March 2018


Contact Info: Editorejo@gmail.com

ISSN Print: 1012-5574

ISSN Online: 2090-8539

Medknow

 **Wolters Kluwer**



Endoscopic detection of fast mucociliary pathways in endoscopic sinus surgery: a marker for local mucociliary function

Sameh M. Amin, Amr A. Baky, Tamer O. Fawzy, Mohamed Hussein

Department of Otorhinolaryngology, Fayoum University, Fayoum, Egypt

Correspondence to Sameh M. Amin, MD, Department of Otorhinolaryngology, Fayoum University, 128 Gisir El Suis Heliopolis, Fayoum, 11321, Egypt. Tel: +20 100 661 3574; e-mail: abdelgalils@yahoo.com, drsamehmohamed71@gmail.com

Received 17 July 2017

Accepted 17 November 2017

The Egyptian Journal of Otolaryngology
2018, 34:21–28

Introduction

The mucociliary transport velocity is heterogenous showing areas of slow and fast pathways. The aim of this study was to assess fast mucociliary pathways (FMP) in the maxillary sinus in chronic rhinosinusitis.

Patients and methods

Endoscopic recording of mucociliary clearance (MCC) and FMP was performed on the posterior wall of the maxillary sinus in 22 chronic rhinosinusitis patients subjected to endoscopic sinus surgery and 12 normal volunteers undergoing septal or turbinate surgery. MCC was assessed intraoperatively using methylene blue over 20 min. MCC was designated as complete, incomplete, or absent. For all patients and controls, the preoperative and postoperative sinonasal outcome scores (SNOT 20) were determined, and the transnasal and transmaxillary saccharin test, and preoperative computed tomography radiological staging were performed.

Results

FMP were more frequent in the controls (75%) than the patients (40%), with no statistical significance. Delay, direction, site, and duration of FMP were not statistically different in both groups. Six patients with no FMP (absent MMC in five and partial in one) had extremely prolonged transmaxillary saccharin times, with no postoperative improvement. Otherwise, SNOT 20, transnasal, and transmaxillary saccharin times improved significantly in the patients. Controls showed a significant improvement in the SNOT 20 and transmaxillary saccharin time. FMP correlated significantly with MCC ($r=0.636$; $P<0.01$), transnasal ($r=-0.7$, $P<0.05$), and transmaxillary ($r=-0.553$; $P<0.05$) saccharin times. In a discriminant model, the only predictive variables of FMP detection were MCC (positive) and transnasal saccharin time (negative) with total correction classification (91.2%). This study describes the different characteristics of FMP. Our results suggest that FMP can be used as a marker of local MCC.

Keywords:

chronic rhinosinusitis, fast mucociliary pathways, functional endoscopic sinus surgery

Egypt J Otolaryngol 34:21–28

© 2018 The Egyptian Journal of Otolaryngology
1012-5574

Introduction

The mucociliary clearance (MCC) is the cornerstone of healthy paranasal sinuses. The ultrastructure and physiology of sinonasal mucosa is well evident in the literature [1]. Restoration of the MMC is the basis of functional endoscopic sinus surgery (FESS). This has been proven in microscopic and ultrastructural studies and to a lesser extent in studies assessing the MCC function [2]. The current investigatory rhinology for MCC entails the Saccharin test, mucociliary transport (MCT) velocity using dyes or radioactive isotopes, ciliary beat frequency (CBF), electron microscopy, and genetic studies. These tests are, however, useful to exclude primary ciliary disorders from chronic rhinosinusitis (CRS). Theoretically, in CRS, it is rather important to differentiate between reversible MCC damage suitable for FESS and irreversible damage necessitating drainage procedures such as endoscopic modified medial

maxillectomy. The latter are used for the treatment of refractory CRS and have been advocated recently for primary CRS with suspected irreversible MC damage [3]. Selection of these cases may require testing of local MCC rather than the overall assessment offered by current MCC investigatory rhinology [4,5]. Direct microscopic and endoscopic visualization has been used to study MCC. Hilding showed areas of inactive and active MCC against gravity [6]. Messklinger showed medial to lateral frontal MCC with recycling at the ostium [7]. Stammberger and Hawke established the common directions of MCC pathways inherent to each paranasal sinus. These MCC pathways are

This is an open access article distributed under the terms of the Creative Commons Attribution-NonCommercial-ShareAlike 3.0 License, which allows others to remix, tweak, and build upon the work noncommercially, as long as the author is credited and the new creations are licensed under the identical terms.

predetermined and fixed as shown in studies using reversed tracheal segments and nasoseptal flaps [8]. The MCC transport velocity is heterogenous. Stammberger and Hawke reported alternating localized areas of slow and fast (express) MCC pathways that can be detected in normal and CRS patients [9]. This finding is not clarified in the literature. The author reported this finding in a cohort of CRS and normal individuals aiming to elucidate a difference or a marker for local MCC impairment.

Patients and methods

This is a prospective observational study for fast mucociliary pathways (FMP) in a group of CRS patients undergoing FESS and controls of volunteers who were candidates for endoscopic inferior turbinate surgery and/or septoplasty with no symptoms of CRS, free computed tomography (CT) scanning of paranasal sinuses, and a normal saccharine test. Approval from the Ethical Committee Faculty of Medicine, Fayoum University, Egypt (code number M89), and informed consent from each participant were obtained.

Inclusion criteria

Evidence of CRS was established by the presence of symptoms for more 3 months, nasal endoscopy, and CT scanning after a thorough medical treatment.

Exclusion criteria

- (1) Suspected primary ciliary dyskinesia (PCD) and cystic fibrosis were evidenced by symptoms and saccharine test.
- (2) Nasal tumors or severe pathology destroying the mucociliary blanket.

All patients and controls underwent preoperative CT of the paranasal sinuses with the Zinreich radiological staging system for CRS (modification of Lund-Mackey) [10]. A validated sinonasal outcome test (SNOT 20) [11], and transnasal and transmaxillary saccharin test were performed preoperatively and 6 months postoperatively.

Sinonasal outcome test 20

The SNOT 20 is a self-administered multiple-choice 20-item test that is usually scored with a single summary score (0–5) with a maximum total score of 100.

It is one of the most widely used quality-of-life instruments for sinonasal conditions and is intended for populations with rhinosinusitis, rather than simple rhinitis.

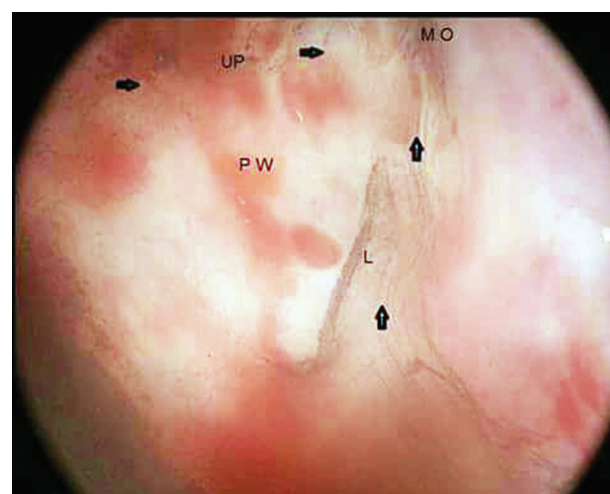
Zinreich radiological computed tomography staging

Each sinus is assigned a score on the basis of the percentage of opacification from mucosal thickening as follows: 0=0%, 1=1–25%, 2=26–50%, 3=51–75%, 4=76–99%, and 5=100% or completely opacified. The osteomeatal complex is assigned a score of 0–2, depending on whether it is completely patent, partially obstructed, or completely obstructed. Each side is graded and their sum is the total score out of a maximum of 54.

Endoscopic recording of fast mucociliary pathways and mucociliary clearance

Patients received hydration with intravenous fluids under general anesthesia at normal body temperature. A trocar and a cannula were inserted into the canine fossa before any manipulation and without aspiration of mucus to preserve the mucociliary function. Methylene blue dye 0.5 ml (methylthionium chloride 5%) (Salix Co., Cairo, Egypt) was injected into the floor of the maxillary sinus after 15 min. MCC and FMP were recorded from the posterior wall of the maxillary sinus for 20 min using a high-definition camera (Telecam-C, 30 mm, SNGF; Karl Storz, Tuttlingen, Germany) and a 0 angle telescope (Karl Storz Hopkins) with 4 mm diameter and 18 cm length. Video recordings were analyzed by two otorhinolaryngologists for the FMP site, direction, latent period, and duration. FMP were defined as directly visible areas of fast dye and movement that can be visualized instantly in comparison with slow MCC clearance that needs tracing dye over the total observation period (Fig. 1).

Figure 1



Endoscopic view of posterior wall (PW) of right maxillary sinus. Horizontal and vertical arrows showing upper (UP) and lower (L) FMP towards maxillary ostium (MO).

Results were interpreted as follows:

- (1) Complete MCC: disappearance of dye from the maxillary sinus and appearance in the middle meatus.
- (2) Partial (incomplete) MCC: movement of the dye reaching the ostium with appearance of the dye in the middle meatus.
- (3) No MCC: absence of any movement of dye.

Transnasal saccharin test

A saccharin particle measuring 1 mm in diameter was placed under direct vision, on the medial surface of the inferior nasal turbinate, at least 1 mm behind the anterior end of the turbinate. The position of the patient had to be such that the head is flexed 10°. The patient was instructed not to sniff, sneeze, cough, smoke, eat, or drink during the test. Patients were asked to report the taste as soon as it was noted. The time from the placement of the saccharin particle to the initial perception of the sweet taste was recorded in minutes. The test was terminated after 60 min. If the taste is not experienced after 60 min, the test should be stopped and the ability of the patient to taste saccharin directly on the tongue is verified [12].

Transmaxillary saccharin test

A 1 cm xylocaine 10% soaked cotton pledget was applied only at the site of the puncture of the inferior meatus to avoid affecting of MCC. A fine trochar and cannula were used to puncture the inferior meatus about 2 cm behind the anterior end of the inferior turbinate and left in place for 20 min. The cannula was then directed to the lateral wall, withdrawn a few millimeters, and redirected toward the floor, where 1 ml of saccharin solution with a high concentration (0.67 g/ml water) was injected through the cannula. With the patient in the sitting position, a measurement was made of the time required for the sweet taste to be identified by the patient considering

an intact taste sensation. If a patient had still not tasted the sweetness after 120 min, the patient was sent home, with instructions to report the time of identification of the sweet taste at the time of the next visit to the hospital. Such patients were also firmly instructed not to lie down, exercise or run, or consume food for 120 min after returning home. The results for such cases were recorded as 'more than 120 min' [13].

Sample size

Calculation of the sample size was carried out using the G*power 3.1.7 product of (Heinrich Heine University, Düsseldorf, Germany), assuming an α -error with a power of calculation of 80% and an allocation ratio of 0.5. The sample size was 34 cases classified into 22 patients and 12 controls. This was based on an initial pilot study.

Statistical analysis

Statistical analyses were carried out using IBM SPSS Statistics for Windows, Version 20.0 (IBM Corp., Armonk, New York, USA) The Kolmogorov–Smirnov test for (nonparametric methods) and the *t*-test for (parametric methods) were used, with levels of significance of 0.05 and 0.01) considered significant and highly significant, respectively. Correlations were established between different variables using the Pearson correlation coefficient. Statistical effects of different variables on FMP were assessed using a discriminant model and confirmed using the χ^2 -test.

Results

Patients and controls had homogenous ($P > 0.05$) demographic data (Table 1). The mean age of the CRS patients was 26.9 years and there were 13 women and nine men. A total of 20 were nonsmokers and two were smokers. The duration of symptoms ranged from 35 to 62 months. The Zinreich staging score range was 5–41. Seven

Table 1 Testing for homogeneity of the sample in terms of age, sex, and smoking

	Patients	Controls	Test	Significance
Age (mean)	26.955	28.667	<i>t</i> -test=0.710 df=32	0.483 $P > 0.05$
Age (SE)	1.307	2.230		
Age (CI for mean 95%)				
UL	29.67	33.58		
LL	24.24	23.76		
Sex [<i>n</i> (%)]				
Female	13 (59.1)	11 (91.7)	KS test=0.908	0.382 $P > 0.05$
Male	9 (40.9)	1 (8.3)		
Smoking status [<i>n</i> (%)]				
Non smoker	20 (90.9)	12 (100)	KS test=0.253	0.997 $P > 0.05$
Smoker	2 (9.1)	–		

CI, confidence interval; KS, Kolmogorov–Smirnov; LL, lower limit; UL, upper limit.

patients had bilateral pan sinusitis, two had unilateral pan sinusitis, 12 patients had bilateral isolated maxillary sinusitis, and one had unilateral isolated maxillary sinusitis. All patients received repeated courses of antibiotics, local decongestants, and steroids. All patients had undergone uncinectomy and middle meatal antrostomy. Nine patients had allergic rhinitis. The mean age of the controls was 28.6 years and there were 11 women and one man. All were nonsmokers. Seven individuals had allergic rhinitis. Nine individuals had septal deviation and five individuals had hypertrophied inferior turbinates.

Preoperative and postoperative sinonasal outcome test score, transnasal saccharin time, and transmaxillary saccharin time

The SNOT 20 scores were higher preoperatively in CRS patients than the controls ($P<0.01$), but not postoperatively ($P>0.05$). Both CRS patients and controls had higher preoperative than postoperative SNOT 20 scores ($P<0.01$) (Table 2).

CRS patients had higher preoperative and postoperative transnasal saccharin test (TNST) times than the controls ($P<0.01$). The preoperative and postoperative TNST in the controls was not statistically different ($P>0.05$), although they showed improvements. The CRS patients had shorter TNST postoperatively ($P<0.01$).

The preoperative and postoperative TMST time was higher in CRS patients than the controls ($P<0.01$

and <0.05), respectively. The TMST time was significantly shorter postoperatively in CRS patients and controls ($P<0.01$ and <0.05), respectively.

Endoscopic assessment of mucociliary clearance and fast mucociliary pathways

FMP detection was more common in controls (75%) than CRS patients (40.9%), although statistically nonsignificant ($P>0.05$). There was no statistically significant difference between the two groups in FMP frequency, MCC result, site, direction, latent period, and duration ($P>0.05$) (Table 3).

Among the CRS patients, nine had FMP (three with complete and six with partial MCC). A total of 13 CRS patients had no FMP (eight had negative MCC and five partial MCC). Among the controls, nine individuals had FMP 9 (three with complete and six with partial MCC). Three controls had no FMP (two with partial MCC and one negative MCC).

FMP were detected in six (27.3%) CRS patients in the lower part and in seven (31.3%) CRS patients in the upper part of the posterior wall of the maxillary sinus. FMP were detected in seven (58.3%) controls in the lower part and in four (33.3%) controls in the upper part of the posterior wall of the maxillary sinus. FMP were detected in four CRS patients and two controls in both the upper and the lower parts of the posterior wall of the maxillary sinus.

Table 2 Preoperative and postoperative sinonasal outcome test 20 score, transnasal saccharin time, and transmaxillary saccharin time

Groups	Code	Descriptive statistics							
		Snot 20 score		Transnasal saccharin time		Transmaxillary saccharin time			
		Mean	SE	Mean	SE	Mean	SE		
Patients /preoperative	A	49.409	2.736	12.968	1.516	57.00	8.500		
patients/postoperative	B	4.409	0.884	11.136	1.201	51.909	9.168		
Controls/preoperative	C	29.167	3.667	7.750	0.939	29.417	1.345		
Controls/postoperative	D	2.500	0.557	6.833	0.649	26.333	1.054		
Comparisons									
Groups	SNOT 20 score			Transnasal saccharin time			Transmaxillary saccharin time		
	Test statistics (t-value)	Significance	Comment	Test statistics (t-value)	Significance	Comment	Test statistics (t-value)	Significance	Comment
AxB	21.394 (21)	0.000 ($P<0.01$)	A>B	3.450 (21)	0.002 ($P<0.01$)	A>B	5.070 (21)	0.000 ($P<0.01$)	A>B
AxC	4.411 (32)	0.000 ($P<0.01$)	A>C	2.926 (31)	0.006 ($P<0.01$)	A>C	3.205 (22)	0.004 ($P<0.01$)	A>C
BxD	1.826 (31)	0.077 ($P>0.05$)	B=D	3.151 (30)	0.004 ($P<0.01$)	B>D	2.771 (21)	0.011 ($P<0.05$)	B>D
CxD	7.836 (11)	0.000 ($P<0.01$)	C>D	2.030 (11)	0.067 ($P>0.05$)	C=D	2.679 (11)	0.021 ($P<0.05$)	C>D

SNOT 20, sinonasal outcome test 20.

Table 3 Mucociliary clearance, fast mucociliary pathways and direction, site, latent period, and duration of fast mucociliary pathways

Groups clearance	Patients (group 1)	Controls (group 2)	KS test	Significance				
Mucociliary clearance [<i>n</i> (%)]								
Negative	8 (36.4)	1 (8.3)	0.781	0.575 ($P>0.05$)				
Positive	14 (63.6)	11 (91.7)						
Time of clearance [<i>n</i> (%)]								
Negative	8 (36.4)	1 (8.3)	0.781	0.575 ($P>0.05$)				
Incomplete	11 (50)	8 (66.7)						
Complete	3 (13.6)	3 (25.0)						
Fast pathways [<i>n</i> (%)]								
Negative	13 (59.1)	3 (25.0)	3.622	0.328 ($P>0.05$)				
Positive	9 (40.9)	9 (75.0)						
Direction of the fast pathway [<i>n</i> (%)]								
Toward the maxillary ostium	8 (88.9)	7 (77.8)	0.236	0.998 ($P>0.05$)				
Away from the maxillary ostium	1 (11.1)	2 (22.2)						
Site of the fast pathway [<i>n</i> (%)]								
Lower part	6 (27.3)	7 (58.3)						
Upper part	7 (31.8)	4 (33.3)						
Latent period and duration of FMP								
	Latent period in minutes							
	Lower part		Upper part		Duration of the fast pathway in minutes			
					Lower part		Upper part	
	Patients	Controls	Patients	Controls	Patients	Controls	Patients	Controls
Mean	7.753	11.797	2.903	7.665	6.723	4.250	8.103	3.750
SE	4.132	8.891	2.105	5.576	2.865	1.022	2.693	1.181
CI for mean 95%								
UL	18.38	33.55	8.06	25.41	14.08	6.75	14.69	7.51
LL	2.86	9.96	2.25	10.08	0.64	1.75	1.51	0.01
<i>t</i> -Test (df)	0.389 (11)		0.964 (9)		0.813 (6)		1.480 (7)	
Significance	0.704 ($P>0.05$)		0.360 ($P>0.05$)		0.446 ($P>0.05$)		0.177 ($P>0.05$)	

Note that there were four CRS patients and two controls with FMP in both the upper and the lower parts of the posterior wall of the maxillary sinus; CI, confidence interval; CRS, chronic rhinosinusitis; FMP, fast mucociliary pathways; KS, Kolmogorov–Smirnov; LL, lower limit; UL, upper limit.

Among the CRS patients, three had complete MCC and ranged from 13 to 18 min. Among the controls, three had complete MCC and ranged from 5 to 12 min.

Variations in the direction of fast pathways (away from the maxillary ostium) were recorded in two controls and one CRS patient.

The duration of FMP ranged from 2 s to 17.40 min, with a total of 97.21 min (22%) of the total recording time, in CRS patients, and 2–8 min, with a total of 44.09 min (18.3%) of the total recording time, in controls. The latent period ranged from 10 s to 19.5 min among the CRS patients and from 5 s to 18.15 min among the controls.

Correlations between different variables

Correlations were established between different variables (MCC, FMP, direction, latent period, duration of FMP, Zineriech staging system preoperative and postoperative SNOT 20, TNST, and TMST) using the Pearson correlation coefficient.

FMP showed a significant ($P<0.05$) positive correlation with MCC ($r=0.636$) complete ($r=0.436$) and an incomplete ($r=0.354$), highly significant ($P<0.01$) strong negative correlation with preoperative and postoperative TNST ($r=-0.700$) ($r=-0.679$), respectively, and a significant ($P<0.05$) negative correlation with TMST preoperatively ($r=-0.553$) and postoperatively ($r=-0.515$).

TMST showed a highly significant ($P<0.01$) positive correlation with TNST preoperatively ($r=0.657$) and postoperatively ($r=0.672$) and a significant ($P<0.05$) negative correlation with MCC preoperatively ($r=-0.478$) and postoperatively ($r=-0.437$).

TNST showed a highly significant ($P<0.05$) negative correlation preoperatively ($r=-0.489$) and postoperatively ($r=-0.389$) with MCC.

SNOT 20 did not correlate with any other variables. Surprisingly, the Zineriech staging system had a highly significant ($P<0.01$) strong positive correlation with complete MCC ($r=0.723$).

Effect of variables on fast mucociliary pathways

The discriminant model is highly significant and was confirmed by the χ^2 -test ($P < 0.01$).

The variables affecting the discrimination model (ranked according to their importance for the model) were as follows:

- (1) Partial MCC (positive effect).
- (2) Transnasal saccharin time (negative effect).

The above two variables affected the FMP (dependent variable), which was confirmed by an increase in the canonical correlation and a decrease in Wilks λ , total correction classification (91.2%).

All CRS patients showed a significant improvement in postoperative SNOT 20 and TNST. All CRS patients (except six) showed improved postoperative TMST. These six cases had even no detected pre and postoperative TMST over 2 h (severe impairment), five cases of them had negative MCC and one case had incomplete MCC. All these six cases had negative FMP. All controls showed a significant improvement in postoperative SNOT 20, TMST. TNST improved postoperatively in the controls, although this was statistically nonsignificant.

Discussion

This study was carried out to detect the different characteristics of the FMP phenomenon in CRS patients and controls. Patients and controls showed homogenous demographic data, with no statistically significant differences. CRS was well evident in the patient group.

MCC and FMP were assessed by direct visualization using methylene blue dye over a period of 20 min. This technique was used by other studies for the endoscopic assessment of MCC in the maxillary sinus [14–16]. This technique showed a significant correlation with radio-labeled scintigraphy. The period of observation has been shown to be sufficient for complete clearance of the mucus blanket [2]. The presence of partial MMC in CRS patients and controls with no FMP excludes cilia paresis as a cause of absent FMP. FMP were detected endoscopically even in the absence of methylene blue.

MCC was further assessed by TNST and TMST. TNST is a standardized test used to exclude pathophysiological disorders of mucociliary activity such as PCD [12]. TMST was performed in an

attempt to identify local MCC impairment in comparison with TNST, which projects general sinonasal MCC. TMST is not commonly used in practice or standardized. Asai *et al.* [13] were the first to use TMST to show local improvements in MCC in the maxillary sinus after FESS. This was confirmed by scanning electron microscopy of the maxillary sinus mucosa. They suggested that TMST can enable decision making on the best subsequent therapeutic approach for CRS patients [13]. TMST had a positive correlation with TNST and a negative correlation with MCC. Surprisingly, among the controls, TMST improved significantly. This may be because of correction of nasal pathology (septal correction) with improved MCC from the middle meatus even in the absence of CRS.

This study is the first to document the different characteristics of FMP (site, direction, duration, and latent period) in a cohort of CRS patients and controls.

FMP was less frequent in CRS patients (40.9%) than in controls (75%), although this was not statistically significant. FMP had a high positive correlation with MCC (complete and incomplete) and negative correlation with TNST and TMST preoperatively and postoperatively. MCC and TNST had a statistically significant effect on FMP detection. This suggests that endoscopic detection of FMP is an indicator and endoscopic marker for good MCC function.

Patients and controls with complete MCC had multiple sites and the longest duration of FMP. All CRS patients had improved postoperative SNOT 20 and TNST. All CRS patients had improved postoperative TMST, except six cases. These six cases had no FMP and no preoperative and postoperative TMST were detected over 2 h (severe impairment); five of these patients had negative MCC and one patient had incomplete MCC. The two smoking CRS patients were among these six patients. Although these data lack statistical significance, they suggest that absent FMP as well as MCC and extreme prolongation of TMST are associated with severe local MCC impairment.

There were variations in the direction of FMP. FMP and MCC were directed toward the natural maxillary ostium, except in two controls and one CRS patient. Similar results were reported by the Messerklinger [7] study of MCC pathways in the frontal sinus. Surprisingly, the Zineriech staging system showed a highly significant strong positive relationship with complete MCC.

Review of the available literature showed no reports characterizing or explaining the mechanism of the FMP phenomenon in paranasal sinuses. However, studies assessing the mucociliary transport of single particles in animal models showed variable speeds, with preferential travel to the ventral surface of the trachea [17]. The FMP phenomena can be expressed in terms of heterogeneous MCT velocity. The MCC in humans and animals occurs generally in two phases: a fast phase and a slow phase. In the nose and PNS, the fast phase of MCC has an average half-time of 16 min, whereas the slow phase has an average half-time of 10 h [18]. Preservation of the fast phase of MCC is an indicator of healthy MCC. In PCD patients, the fast phase of MCC is retarded and prolonged [19]. The explanation for the fast phase of the upper airway is unclear, but it could be explained by many variables such as CBF, periciliary liquid, length of cilia, pattern of MCC, mucus properties, and particle size.

The effect of CBF on MCT velocity is controversial. Initial studies have shown the presence of slow-beating and fast-beating cilia [20]. Some studies correlated pharmacological induction of increased CBF *in vitro* with increased *in-vivo* MCT velocity. Other studies have debated this correlation because CBF was relatively similar across multiple regions in the presence of different MCT velocities assessed *in vivo* [17,21,22]. Detection of considerable variability in the rates and viscosity of secretion from the submucosal glands and mucus thickness was hypothesized to be a possible cause. Heterogeneity in MCT was also attributed to variable depths of periciliary liquid, but this is disproved by finding variable speed of individual particles over the same areas of the mucociliary blanket [17]. Deposited particles larger than 6 µm are generally cleared from the airways within 24 h, whereas smaller particles are retained for longer durations [19,23]. Other studies showed that particle size seemed to be relatively uncritical for MCT in comparison with particles-related surface chemistry [24].

The FMP phenomena could be one of the explanations for the fast phase of MCC, which is well documented in the literature. Further research is needed to confirm this assumption.

Conclusion

The current study is the first to describe the FMP phenomenon and its characteristics. Our results suggest that endoscopic detection of FMP is an indicator of good MCC. The absence of FMP was

associated with undetectable TMST and MCC. If this is proven in a large sample, it might help to differentiate cases of CRS who may benefit from functional versus drainage procedures.

Financial support and sponsorship

Nil.

Conflicts of interest

There are no conflicts of interest.

References

- Cohen NA. Sinonasal mucociliary clearance in health and disease. *Ann Otol Rhinol Laryngol Suppl* 2006; 196:20–26.
- Bizaki AJ, Numminen J, Taulu R, Rautiainen M. A controlled, randomized clinical study on the impact of treatment on antral mucociliary clearance: uncinctomy versus balloon sinuplasty. *Ann Otol Rhinol Laryngol* 2016; 125:408–414.
- Wang EW, Gullung JL, Schlosser RJ. Modified endoscopic medial maxillectomy for recalcitrant chronic maxillary sinusitis. *Int Forum Allergy Rhinol* 2011; 1:493–497.
- Bassiouni A, Naidoo Y, Wormald PJ. When FESS fails: the inflammatory load hypothesis in refractory chronic rhinosinusitis. *Laryngoscope* 2012; 122:460–466.
- Chen B, Antunes MB, Claire SE, Palmer JN, Chiu AG, Kennedy DW, Cohen NA. Reversal of chronic rhinosinusitis-associated sinonasal ciliary dysfunction. *Am J Rhinol* 2007; 21:346–353.
- Hilding A. The flow of the mucus currents through the drainage system of the nasal mucosa and its relation to ciliary activity. *Arch Otolaryngol* 1932; 15:92–100.
- Messerlinger W. On the drainage of the normal frontal sinus of man. *Acta Otolaryngol* 1967; 63:176–181.
- Ateşpare A, Üstündağ E, Dalçık H, Çelik Ö. Mucociliary transport and histopathological changes in rotation flaps of the nasal mucosa. *Eur Arch Otorhinolaryngol* 2015; 272:1143–1148.
- Stammberger H, Hawke M. *Essentials of endoscopic sinus surgery*. St. Louis: Mosby 1993.
- Likness MM, Pallanch JF, Sherris DA, Kita H, Mashtare TL Jr, Ponikau JU. Computed tomography scans as an objective measure of disease severity in chronic rhinosinusitis. *Otolaryngol Head Neck Surg* 2014; 150:305–311.
- Pynnonen MA, Kim HM, Terrell JE. Validation of the Sino-Nasal Outcome Test 20 (SNOT-20) domains in nonsurgical patients. *Am J Rhinol Allergy* 2009; 23:40–45.
- Rutland J, Cole PJ. Nasal mucociliary clearance and ciliary beat frequency in cystic fibrosis compared with sinusitis and bronchiectasis. *Thorax* 1981; 36:654–658.
- Asai K, Haruna S, Otori N, Yanagi K, Fukami M, Moriyama H. Saccharin test of maxillary sinus mucociliary function after endoscopic sinus surgery. *Laryngoscope* 2000; 110:117–122.
- Thulasidas P, Vaidyanathan V. Role of modified endoscopic medial maxillectomy in persistent chronic maxillary sinusitis. *Int Arch Otorhinolaryngol* 2014; 18:159–164.
- Yazici H, Soy FK, Kulduk E, Doğan S, Dündar R, Sakarya EU, Can IH. Comparison of nasal mucociliary clearance in adenoid hypertrophy with or without otitis media with effusion. *Int J Pediatr Otorhinolaryngol* 2014; 78:1143–1146.
- Griffa A, Berrone M, Boffano P, Viterbo S, Berrone S. Mucociliary function during maxillary sinus floor elevation. *J Craniofac Surg* 2010; 21:1500–1502.
- Hoegger MJ, Awadalla M, Namati E, Itani OA, Fischer AJ, Tucker AJ, et al. Assessing mucociliary transport of single particles *in vivo* shows variable speed and preference for the ventral trachea in newborn pigs. *Proc Natl Acad Sci USA* 2014; 111:2355–2360.
- Smith JRH, Etherington G, Shutt AL, Youngman MJ. A Study of aerosol deposition and clearance from the human nasal passage. *Ann Occup Hyg* 2002; 46(Suppl 1):309–313.
- Möller W, Häussinger K, Ziegler-Heitbrock L, Heyder J. Mucociliary and long-term particle clearance in airways of patients with immotile cilia. *Respir Res* 2006; 7:10.

- 20 Veale D, Rodgers AD, Griffiths CJ, Ashcroft T, Gibson GJ. Variability in ciliary beat frequency in normal subjects and in patients with bronchiectasis. *Thorax* 1993; 48:1018–1020.
- 21 Boek WM, Graamans K, Natzijl H, van Rijk PP, Huizing EH. Nasal mucociliary transport: new evidence for a key role of ciliary beat frequency. *Laryngoscope* 2002; 112:570–573.
- 22 Zhang L, Han D, Song X, Wang K, Wang H. Effect of oxymetazoline on healthy human nasal ciliary beat frequency measured with high-speed digital microscopy and mucociliary transport time. *Ann Otol Rhinol Laryngol* 2008; 117:127–133.
- 23 Möller W, Häussinger K, Winkler-Heil R, Stahlhofen W, Meyer T, Hofmann W, Heyder J. Mucociliary and long-term particle clearance in the airways of healthy nonsmoker subjects. *J Appl Physiol* (1985) 2004; 97:2200–2206.
- 24 Henning A, Schneider M, Nafee N, Muijs L, Rytting E, Wang X, *et al.* Influence of particle size and material properties on mucociliary clearance from the airways. *J Aerosol Med Pulm Drug Deliv* 2010; 23:233–241.