



Original Article

# Single Stage Canal Wall Down Mastoidectomy with Reconstruction of the Canal Wall: 5 Years' Experience in Fayoum Province, Egypt

Mohamed Qotb, Tamer Fawzy, Waleed Ragab

Department of Ear Nose and Throat, Fayoum University, Fayoum, Egypt

**Cite this article as:** Qotb M, Fawzy T, Ragab W. Single Stage Canal Wall Down Mastoidectomy with Reconstruction of the Canal Wall: 5 Years' Experience in Fayoum Province, Egypt. J Int Adv Otol 2017; 13: X-X.

**OBJECTIVE:** Removing the posterior canal wall or canal wall down mastoidectomy (CWDM) for the management of cholesteatoma remains controversial. We advocate partial removal of the posterior canal wall for complete eradication, followed by canal wall defect reconstruction to restore the normal anatomy and avoid the complications of CWDM.

**MATERIALS and METHODS:** Sixty-four patients with cholesteatoma (71 ears) were included. This study was conducted between 2009 and 2012. Single-stage mastoidectomy was performed by drilling the upper third of the posterior canal wall together with the attic, leaving the remaining lower two-thirds intact. Conchal cartilage was used to reconstruct the upper third of the posterior canal wall.

**RESULTS:** The mean±SD healing time was 7.5±2.3 (range, 4–14) weeks. The mean±SD preoperative and postoperative air bone gaps were 35.8±6.2 dB and 22.9±6.8 dB, respectively. Nearly 84.2% of the patients were followed up for at least 3 years and had dry healthy ears. Complications were noted and statistically examined.

**CONCLUSION:** Single-stage CWDM with reconstruction of the posterior canal wall, ossicular chain, and tympanic membrane is a safe and reliable technique with the advantages of Canal wall up Mastoidectomy (CWUM). Its recurrence rate is 4.2%. Longer follow-up durations are required.

**KEYWORDS:** Cholesteatoma, posterior canal wall reconstruction, mastoidectomy, mastoid obliteration

## INTRODUCTION

The management of cholesteatoma remains controversial. The primary objective in the management is the complete eradication of the disease and creation of a safe ear <sup>[1]</sup>. Additional objectives include preservation of hearing and restoration of normal middle ear and external auditory canal morphologies for providing an improved quality of life <sup>[2]</sup>. Many experienced surgeons continue to debate whether the posterior canal wall should be preserved or removed.

Canal wall up Mastoidectomy (CWUM) preserves the normal anatomy and reduces the healing time; on the other hand, it has high residual or recurrence rates (26–45%) due to the limited surgical view. It may also require “second-look” surgery for reconstructing the ossicular chain six months later <sup>[3,4]</sup>.

For many years, Canal wall down Mastoidectomy (CWDM) was considered to be the gold standard for the management of cholesteatoma. It allows for excellent visualization of the disease and complete removal, with a very low recurrence rate in the single-stage procedure. However, CWDM has a significant morbidity risk. Its complications include open cavity problems such as persistent otorrhea, keratin debris accumulation, caloric stimulation, inferior hearing, and difficulty in hearing aid fitting. To resolve this controversial issue, many surgeons have opted to lower the posterior canal wall to the level of the facial nerve for the management of cholesteatoma, followed by mastoid obliteration, with reconstruction of the posterior canal wall, ossicular chain, and tympanic membrane <sup>[5,6]</sup>.

Several mastoid obliteration techniques have been used, including muscle flaps, cortical bone pate, autologous bone chips, and hydroxyappetite <sup>[7,8]</sup>. Mastoid obliteration provides a better quality of life as opposed to an unobliterated open cavity.

**Corresponding Address:** Tamer Fawzy E-mail: drfawzyt@gmail.com

**Submitted:** 15.12.2016

**Revision received:** 11.05.2017

**Accepted:** 13.07.2017

©Copyright 2017 by The European Academy of Otology and Neurotology and The Politzer Society - Available online at www.advancedotology.org

At a university teaching hospital in southern Egypt, we perform over 30 mastoidectomies annually. CWDM with reconstruction of the posterior wall and mastoid obliteration with or without ossiculoplasty has been our selected technique. All surgeons participating in the present study had more than 10 years of experience in middle ear and mastoid surgeries at initiation of this study.

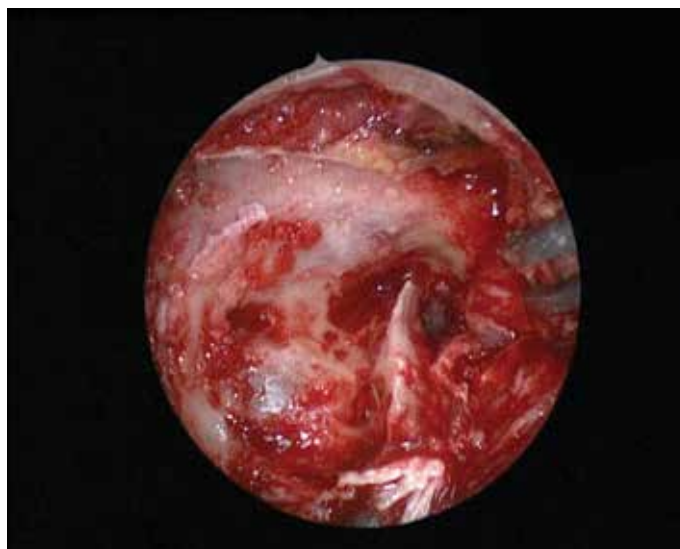#### MATERIALS and METHODS

Sixty-four patients with cholesteatoma were included. Data including age, gender, pre- and postoperative audiograms, radiologic findings, surgical procedure, and surgical results with regards to recurrence and residual rates and complications such as retraction pocket, perforation, and infection were obtained. Audiometric data are presented as pure-tone average air-bone gap (Avg-ABG) calculated at 500, 1000, 2000, and 4000 Hz. All patients provided signed consent for every procedure and the likelihood of potential complications. All patients have a history of intermittent for at least 5 years and an average of 9 and 2 months. They are mostly neglected patients who have not had access to proper healthcare for years. All our patients underwent either preoperative CT scans or an X-ray Schuler view of the mastoid. No patients had a well-pneumatized mastoid. Twenty-four patients had a contracted mastoid. Eleven patient had a history of mastoid abscess. None of the patients had limited attic cholesteatoma in their dry ear. They were not excluded; we rarely observe them in our outpatient department. Ethics committee approval was received for this study from the ethics committee of Fayoum University, Medical school, Egypt. Informed consent was obtained from who participated in this study.

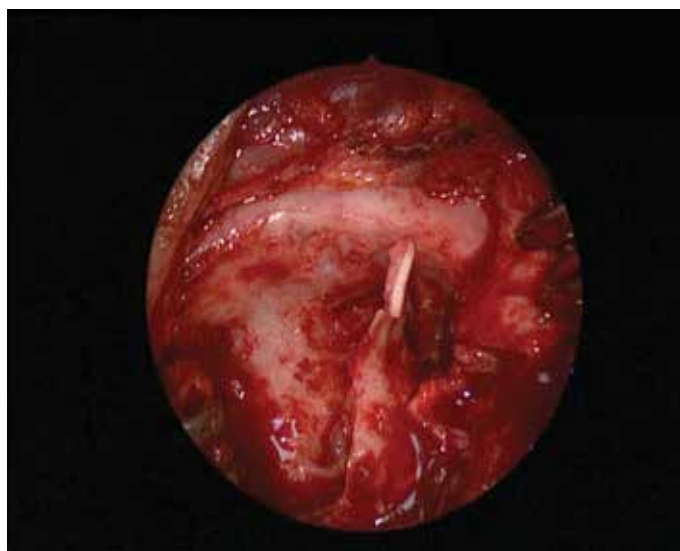#### Surgical Technique

The traditional postauricular approach was used. Two grafts are harvested from the superficial and deep temporalis fascia. A wide tympanomeatal flap is elevated. The middle ear is entered, and occasionally, canaloplasty is performed. Complete mastoidectomy is performed. Bone pate is collected in a basin during mastoidectomy from the healthy, disease-free mastoid cortex and is set aside. The cholesteatoma is completely removed from the mastoid along with the granulation tissue. The upper third of the posterior canal wall together with the attic (epitympanum) is drilled out, leaving the remaining lower two-thirds intact. At this point, the epitympanum is completely exposed. The incus remnants and malleus are removed. The remaining cholesteatoma is carefully removed from the epitympanum, stapes, oval window, and facial canal. The sinus tympani is thoroughly observed for cholesteatoma to avoid recurrence using an otoendoscope. The previous technique allows for complete removal of the cholesteatoma without the need for complete CWDM (Figure 1). At this point, a generous piece of conchal cartilage is harvested and its perichondrium is removed. The cartilage is cut into two pieces and is used to reconstruct the upper third of the posterior canal wall and attic. Preserving the lower two-thirds of the posterior canal wall helps support the conchal cartilage. Because of its curvature, it is ideal for reconstruction (Figure 2). The mastoid cavity and epitympanum are carefully obliterated by the autologous bone pate collected during mastoidectomy. The bone pate also acts as a support for the reconstructed posterior wall.

Primary ossicular reconstruction is performed for all patients using partial ossicular replacement prosthesis (PORP) or total ossicular replace-



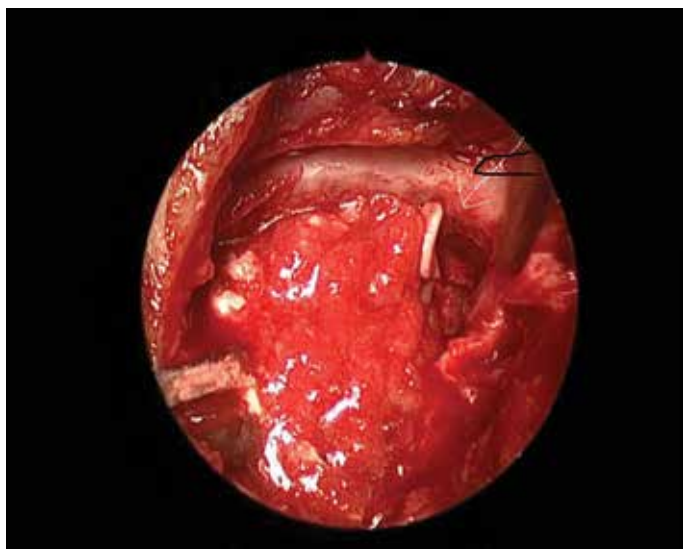
**Figure 1.** The upper one-third of the posterior canal wall together with the attic (epitympanum) is drilled out leaving the remaining lower two-thirds intact.



**Figure 2.** Conchal cartilage in place over the intact lower two-thirds before placement of temporalis fascia.

ment prosthesis (TORP) depending on the presence or absence of stapes suprastructures. It is performed even if second-look surgery is planned. The prosthesis helps maintain the middle ear space and support the reconstructed wall cartilage. The superficial layer of the temporalis fascia is used to provide a soft tissue cover over the conchal cartilage, while the deep temporalis fascia is used to reconstruct the tympanic membrane (Figure 3). Gelfoam soaked with antibiotics and steroids is inserted medially and laterally to the new tympanic membrane.

Meatoplasty is not performed. The canal is packed with gauze soaked with antibiotic ointment. The wound is closed in two layers, and a standard mastoid dressing is applied. Patients are given oral quinolone antibiotics for 1 week. The gelfoam is removed after 7 days. Patients are followed up on a weekly basis to assess healing by otoendoscopy. After 2 weeks, patients are asked to start performing the Valsalva maneuver to clinically assess drum mobility and to prevent tympanic membrane retraction.



**Figure 3.** Conchal cartilage and temporalis fascia placement for reconstruction of the upper one-third of the posterior canal wall together with the attic (epitympanum)

**Table 1.** Patient demographics

Total number of patients	64
Total number of ears	71
Number of patients with bilateral pathology	7
Mean±SD age (range), years	33±7.5 (20–45)
Male, n (%)	41 (64%)
Female, n (%)	23 (36%)
PORP, n (%)	47 (71%)
TORP, n (%)	24 (29%)
Ventilation tubes, n (%)	13 (18.3%)
Mean±SD healing time (range)	7.5±2.4 (4–14)
Mean±SD follow-up period (range)	34.2±13 (10–55)

SD: standard deviation; PORP: partial ossicular replacement prosthesis; TORP: total ossicular replacement prosthesis

**Table 2.** Hearing results

ABG	Min.	Max.	Mean±standard deviation
Preoperative	24	48	35.9±6.2
Postoperative	12	40	22.9±6.8
Significance		p<0.001	r=0.584

Min: minimum; Max: maximum; ABG: air-bone gap

Postoperative hearing is assessed by audiometry, while drum mobility is assessed by tympanometry after 1, 6, and 12 months. Preoperative and postoperative average ABGs are calculated at 500, 1000, 2000, and 4000 Hz. Healing of the canal wall and tympanic membrane, together with complications such as cholesteatoma recurrence, is observed and recorded clinically and by performing a CT scan if required. Second-look surgery is not routinely performed in all patients; it is performed only when recurrence is suspected.

**Table 3.** Hearing results

Postoperative ABG improvement	No. of patients, n (%)
0–10 dB	0
11–20 dB	41 (57.8%)
21–30 dB	20 (28.1%)
31–40 dB	10 (14.1%)

**Table 4.** Percentage of complications

Complications	Number of patients	Percentage
Infection and bone resorption	2	2.8%
Prosthesis slippage	4	5.6%
Tympanic membrane retraction	9	12.6%
Recurrence	3	4.2%
Residual	0	0%
Total	18	25.2 %

**Statistical Analysis**

Microsoft Excel version 2010 (Redmond, Washington, USA) was used for data entry, and SPSS (IBM Corp.; version 21, New York, USA) software was used for data analysis. Simple descriptive statistics (arithmetic mean and standard deviation) were used to summarize quantitative data and frequencies were used to summarize qualitative data. Bivariate relationships were displayed in cross-tabulations; the comparison of proportions was performed using the chi-squared test. The independent t-test, one-way ANOVA, the post hoc test, and Pearson correlation tests were used to compare normally distributed quantitative data. A p-value of less than 0.05 was considered statistically significant.

**RESULTS**

Sixty-four patients (71 ears, 41 males and 23 females, mean±SD age: 33±7.5, range: 20–45 years) were (Table 1). Seven patients had bilateral pathology. All surgeries were performed at a university teaching hospital between January 2010 and February 2015. Intraoperatively, all patients had cholesteatoma or keratin extending medially to the long incus process. Labyrinthine fistulas were detected in 2 patients and were successfully managed with temporalis fascia and fat. Subdural abscesses were detected in 6 patients.

The mean±SD healing time was 7.5±2.3 (range, 4–14) weeks. The mean±SD preoperative and postoperative ABGs were 35.9±6.2 dB and 22.9±6.8 dB, respectively. A moderate positive correlation was found between pre- and postoperative ABGs (p<0.001; r=0.584). A highly significant correlation was found between grades of improvement and preoperative and postoperative ABGs (p<0.001) as seen in Tables 2 and 3.

PORP was used 45 times, while TORP was used 26 times. The mean±SD follow-up period was 34.2±13 (range, 10–55) months. A significant correlation was found between the type of prosthesis and grades of improvement of ABG (p<0.05).

Nearly 84.2% of patients were followed up for the 3 postoperative years, and had dry healthy ears with good hearing and without disability. Thirty nine patients (54%) had shallow, self-cleaning, and

safe retraction pockets mostly at the epitympanum. These patients showed no debris collection.

### Complications

Two patients (2.8%) had infection with resorption of the bone pate. In 4 patients (5.6%), TORP slipped off and the tympanic membrane did not close. Nine patients (12.6%) showed severe retraction of the tympanic membrane with conductive hearing loss; these patients typically did not or could not perform the Valsalva maneuver. Recurrence was noted in patients (4.2%) clinically and by CT scans, typically at the epitympanic area. These patients eventually required revision surgery in the form of complete CWDM, without making any attempts of reconstruction, with meatoplasty. As demonstrated in Table 4, no residual cholesteatoma was observed during the follow-up period.

### DISCUSSION

Maintaining or removing the posterior canal wall for managing cholesteatoma remains controversial. Dornhoffer<sup>[9]</sup> proposed a technique and published follow-up reports in 2004 and 2006. His single-stage technique begins by performing atticotomy, and the cholesteatoma is posteriorly followed in the form of retrograde mastoidectomy, during which only the upper third of the posterior wall is removed and then reconstructed using conchal cartilage. Ossiculoplasty with tympanic membrane grafting is simultaneously performed<sup>[10,11]</sup>.

Ganz et al.<sup>[10]</sup> and others used a microsagittal saw to temporarily remove the posterior canal wall to obtain a wide view and replaced it after cholesteatoma extirpation. Bone pate is used to obliterate the mastoid, but ossiculoplasty using cartilage and a titanium prosthesis was performed, usually in a second-look surgery. A recurrence rate of 1.5% and residual rate of 9.8% were reported.

The technique used in our study is slightly different from Dornhoffer's technique as it starts with complete mastoidectomy and collection of the bone pate followed by removal of the upper third of the posterior canal wall to ensure complete cholesteatoma expiration; then, ossiculoplasty and tympanic membrane grafting are performed in a single stage<sup>[12]</sup>.

Advocates of complete CWDM justify its use as it provides a good view of the mesotympanum and sinus tympani to ensure complete expiration of the cholesteatoma and to avoid recurrence. They argue that preserving the posterior canal wall (facial ridge) serves as a mechanical obstruction to self-cleansing, leading to the accumulation of debris and preventing sufficient aeration; therefore, it should be removed<sup>[13,14]</sup>. In contrast to this claim, the incidence of recurrence in the present study (4.2%) appears to be nearly the same or even less than studies advocating the use of CWDM<sup>[15]</sup>. We believe that the development of the otoendoscope, which helps visualize the sinus tympani and various obscure areas, is responsible for the improved results obtained using our technique. Preserving the posterior canal wall (near normal anatomy) allows for the easier reconstruction of the posterior wall with conchal cartilage, without the requirement for sophisticated tools<sup>[16]</sup>. This modification of CWDM favors more physiologic ossiculoplasty using PORP and TORP, better reconstruction results, and support of the new tympanic membrane. Besides, it helps support bone pate filling the mastoid cavity, which is not possible in complete CWDM. By pro-

viding sufficient middle ear space, the reconstructed posterior wall results in a better hearing gain<sup>[11,17]</sup>.

Staging of the procedure is preferred by some authors<sup>[18,19]</sup>. It is used for a second-look operation of the posterior wall or ossiculoplasty. Our results show that it is possible to perform the entire procedure in one sitting, without the necessity for staging. It is more convenient and will reduce the burden on patients, particularly in developed countries. Dornhoffer and others have also advocated the single-stage procedure with comparable results. It has also been argued that each procedure should be tailored according to the intraoperative situation, particularly if there is complete disease expiration is doubtful<sup>[20]</sup>.

Bone pate has been widely used to successfully obliterate the mastoid and epitympanum<sup>[21]</sup>. We found it better to use than other materials as it is easily collected from the non-infected mastoid cortex. Using bone pate or other materials does not affect the outcome, apart from being infected with resorption of the bone. It can be avoided by the application of antibiotic powder on the bone pate before using. Adequate blockage of the attic with a generous piece of cartilage should be performed<sup>[10,22]</sup>.

We found that Eustachian tube (ET) function was very important in predicting the outcome regarding retraction pockets. Patients who could perfectly perform the Valsalva maneuver preoperatively continue to perform it postoperatively. Specifically, these patients did not develop retraction pockets. On the other hand, retraction pockets and recurrent cholesteatoma were noticed in patients who could not or did not perform the Valsalva maneuver. Haginomori et al. reported the importance of the ventilation function of the ET in postoperative aeration of the middle ear<sup>[5]</sup>. However, they did not mention the effect of the Valsalva maneuver and also did not insert ventilation tubes.

Walker et al.<sup>[1]</sup> and Gantz et al.<sup>[10]</sup> did not insert ventilation tubes. They mentioned the effect of poor ET function on the development of retraction pockets. Nevertheless, they stated that it is better for patients to have middle ear effusion than chronic ear discharge.

A study has suggested that retraction pockets are due to the presence of nitrogen-absorbing mucosa<sup>[10]</sup>. We cannot confirm or deny this claim in our study. Some reports have mentioned a 30% decline in hearing after CWDM with mastoid obliteration and reconstruction, while others showed significant improvement in hearing after the single-stage CWDM with reconstruction. Our study demonstrated improved postoperative hearing, which was quantified as a decrease in ABG from an average preoperative value of 35.9 dB to an average postoperative value of 22.9 dB. It is worth mentioning that patients received PORP had better outcomes than those receiving TORP due to the effect of stapes suprastructures on the hearing outcome.<sup>[23,24]</sup> Nevertheless, De Corso et al.<sup>[20]</sup> reported no effect of stapes suprastructures on hearing gain. It should be noted that reconstruction of the posterior canal wall remains a difficult procedure that requires surgical skill.

### CONCLUSION

In our experience, single-stage CWDM with reconstruction of the posterior canal wall, ossicular chain, and tympanic membrane is a

safe and reliable technique that provides the advantages of CWUM and CWDM without their disadvantages. It has recurrence rate of 4.2% with a residual rate of 0%. However, continual training and a longer follow-up period are required.

**Ethics Committee Approval:** Ethics committee approval was received for this study from the ethics committee of Fayoum University, Medical school, Egypt.

**Informed Consent:** Informed consent was obtained from who participated in this study.

**Peer-review:** Externally peer-reviewed.

**Author Contributions:** Concept - M.Q.; Design - T.F.; Supervision - W.R.; Resources - M.Q., W.R.; Materials - M.Q., W.R.; Data Collection and/or Processing - M.Q. T.F.; Analysis and/or Interpretation - M.Q. T.F.; Literature Search - M.Q., W.R.; Writing Manuscript - M.Q. T.F.; Critical Review - T.F.

**Conflict of Interest:** No conflict of interest was declared by the authors.

**Financial Disclosure:** The authors declared that this study has received no financial support.

## REFERENCES

1. Walker PC, Mowry SE, Hansen MR, Gantz BJ. Long-Term results of canal wall reconstruction tympanomastoidectomy. *Otol Neurotol* 2013; 35: 24-30.
2. Heo KW, Kang MK, Park JY. Alternative to canal wall-down mastoidectomy for sclerotic mastoid cavities: epitympanoplasty with mastoid obliteration. *Ann Otol Rhinol Laryngol* 2014; 123: 47-52.
3. Steven YHO, John FK. Efficacy of the 2- Staged Procedure in the Management of Cholesteatoma. *Arch Otolaryngol Head Neck Surg* 2003; 129: 541-5.
4. Cody DT, McDonald TJ. Mastoidectomy for acquired cholesteatoma: follow-up to 20 years. *Laryngoscope* 1984; 94: 1027-9.
5. Haginomori S, Takamaki A, Nonaka R, Mineharu A, Kanazawa A, Takenaka H. Postoperative aeration in the middle ear and hearing outcome after canal wall down mastoidectomy with soft-wall reconstruction for cholesteatoma. *Otol Neurotol* 2009; 30: 478-83.
6. Smyth GDL. Surgical treatment of cholesteatoma: the role of staging closed operations. *Ann Otol Rhinol Laryngol* 1988; 97: 667-9.
7. Sade J, Weinberg J, Berco E, Brown M, Halvey A. The masupialized (radical) mastoid. *J Laryngol Otol* 1982; 96: 869-75.
8. Kurien G, Greeff K, Goma N, Ho A. Mastoidectomy and mastoid obliteration with autologous bone graft: a quality of life study. *J Otolaryngol Head Neck Surg* 2013; 23: 42-9.
9. Dornhoffer JL, Smith J, Richer G, Boeckmann J. Impact on quality of life after mastoid obliteration. *Laryngoscope* 2008; 118: 1427-32.
10. Ganz BJ, Wilkinson EP, Hansen MR. Canal wall reconstruction tympanomastoidectomy with mastoid obliteration. *Laryngoscope* 2005; 115: 1734-40.
11. Lee W, Kim SH, Moon IS, Byeon HK. Canal wall reconstruction and mastoid obliteration in canal wall tympanomastoidectomized patients. *Acta Otolaryngol* 2009; 129: 955-61.
12. Black B. Mastoidectomy elimination: obliterate, reconstruct or ablate? *AM J Otol* 1998; 19: 551-7.
13. American Academy of Otolaryngology-Head & Neck Surgery Foundation, Inc. Committee on Hearing and Equilibrium. Guidelines for the evaluation of results of treatment of conductive hearing loss. *Otolaryngol Head Neck Surg* 1995; 113: 186-7.
14. Dornhoffer J. Retrograde mastoidectomy with canal wall reconstruction: A follow up report. *Otol Neurotol* 2004; 25: 653-60.
15. Smyth GD. Cholesteatoma surgery: the influence of the canal wall. *Laryngoscope* 1985; 95: 92-6.
16. Takahashi H, Hasebe S, Sudo M, Tanabe M, Funabiki K. Soft-wall reconstruction for cholesteatoma surgery: reappraisal. *Am J Otol* 2000; 21: 28-31.
17. Dornhoffer J. Retrograde mastoidectomy with canal wall reconstruction for cholesteatoma removal. *Ann Otol Rhinol Laryngol* 2000; 109: 1033-9.
18. Dornhoffer J. Retrograde mastoidectomy. *Otolaryngol Clin N Am* 2006; 39: 1115-27.
19. Berçin S, Kutluhan A, Bozdemir K, Yalçiner G, Sari N, Karamese O. Results of revision mastoidectomy. *Acta Otolaryngol* 2009; 129: 138-41.
20. De Corso E, Marchese MR, Sergi B, Rigante M, Paludetti G. Role of ossiculoplasty in canal wall down tympanoplasty for middle-ear cholesteatoma: hearing results. *J Laryngol Otol* 2007; 121: 324-8.
21. McElven JT, Chung AT. Reversible canal wall down mastoidectomy for acquired cholesteatoma: preliminary results. *Laryngoscope* 2003; 113: 1027-33.
22. Deveze A, Rameh C, Sanjuan P, Lafont B, Lavieille J, Magnan J. Rehabilitation of canal wall down mastoidectomy using a titanium ear canal implant. *Otol Neurotol* 2010; 31: 220-4.
23. Kos MI, Montandon P, Castrillon R, Guyot JP. Anatomic and functional long-term results of canal wall down mastoidectomy. *Ann Otol Rhinol Laryngol* 2004; 113: 872-6.
24. Minovi A, Venjacob J, Volkenstein S, Dornhoffer JL, Dazert S. Functional results after cholesteatoma surgery in an adult population using the retrograde mastoidectomy technique. *Eur Arch Otorhinolaryngol* 2014; 271: 495-501.